

Non-Surgical, Minimally Invasive, Bone-Borne Rapid Palatal Expansion for Orthopaedic Correction of Transverse Maxillary Deficiency in Young Adults: A Review

Review Article

Patni VJ¹, Kolge NE^{2*}, Potnis SS³, Patil RD⁴, Lokhande AP⁵ and Sawant HR⁶

¹Professor, Department of Orthodontics, MGM Dental College & Hospital, India

²Post Graduate Student, Department of Orthodontics, MGM Dental College & Hospital, India

³Professor, Department of Orthodontics, Sinhgad Dental College & Hospital, India

⁴Post Graduate Student, Department of Orthodontics, Sinhgad Dental College & Hospital, India

⁵Post Graduate Student, Department of Orthodontics, YMT Dental College & Hospital, India

⁶Post Graduate Student, Department of Orthodontics, Bharati Vidyapeeth University Dental College & Hospital, India

*Corresponding author: Kolge NE, Post Graduate Student, Department of Orthodontics, MGM Dental College & Hospital, Navi Mumbai, India, Tel no: +91-8237239060; E-mail: neerajkolge11@gmail.com

Article Information: Submission: 01/02/2019; Accepted: 21/03/2019; Published: 26/03/2019

Copyright: © 2019 Patni VJ, et al. This is an open access article distributed under the Creative Commons Attribution License, which permits unrestricted use, distribution, and reproduction in any medium, provided the original work is properly cited.

Abstract

Traditionally, cases with transverse maxillary expansion are treated with Rapid Palatal Expansion (RPE). As conventional RPE appliances transmit forces using teeth as handles, alveolar bone bending and dental tipping is unavoidable. This is more prominently appreciated in older individuals' due to nearly ossified mid palatal suture causing reduction in the amount of skeletal expansion achieved. Miniscrew Assisted Rapid Palatal Expansion (MARPE) appliances have been developed which confine transverse forces of the appliance to the midpalatal suture and minimizes dental side effects; thus, making them suitable for use in older patients. This paper is a review of the appliance design, appropriate location for placement of miniscrews, insertion technique, activation schedule, post-expansion assessment parameters etc.

Keywords: MARPE; Headless screws

Abbreviations

MARPE: Miniscrew Assisted Rapid Palatal Expansion; RPE: Rapid Palatal Expansion; TAD: Temporary Anchorage Devices

Introduction

Traditionally, cases with transverse maxillary expansion are treated with Rapid Palatal Expansion (RPE) that are a combination of orthopaedic and dental expansion which is used to correct skeletal disharmony [1,2].

Though, many types of RPE appliances have been developed, the principal essentially remain the same [3-5]. As conventional RPE appliances transmit forces using teeth as handles, alveolar bone

bending and dental tipping is unavoidable. This is more prominently appreciated in older individuals due to nearly ossified mid palatal suture causing reduction in the amount of skeletal expansion achieved [6,7].

RPE also leads to clockwise rotation of mandible and opening of the bite. Not much earlier, Miniscrew Assisted Rapid Palatal Expansion (MARPE) appliances have been developed which confine transverse forces of the appliance to the midpalatal suture and minimizes dental side effects; thus, making them suitable for use in older patients [5,8].

MARPE is a simple modification of the conventional RPE appliance; the main difference is the incorporation of several

miniscrews to maximize expansion of the underlying basal bone and minimize dental side effects. MARPE was first introduced by Lee, et al in 2010 reported successful expansion of the maxilla through opening of the midpalatal suture [9,10].

Stress distribution trajectories are mainly along three buttresses in the maxilla; namely zygomaticomaxillary, nasomaxillary and pterygomaxillary. Major disadvantages of conventional RPE appliances include tipping of anchor teeth [11], limited skeletal movements [12], undesirable tooth movement [13], root resorption [14], bony dehiscences and fenestrations as well as post-expansion relapse [15].

Thus, MARPE appliance is beneficial in adult patients with more sutural resistance to skeletal expansion and even in young patients by minimizing or even preventing dental tipping thus avoiding further increase in the vertical dimension and other aforementioned side effects.

Appliance design

Various MARPE designs by Carlson C, Moon W and MacGinnis have been recommended by many authors [16-18]; without any dental support (exclusively bone borne), with support from teeth (teeth-bone borne) and with use of two/four mini screws (Figure 1). They can be prefabricated (commercially available like MSE, etc.) or can be made in the laboratory [10,19-20].

Location of miniscrews

Factors like convenient access, low risk of damage to the surrounding anatomical structures [21-23], high quality cortical bone and thin mucosa confirming adequate stability makes paramedian area (3 mm lateral to the suture in 1st premolar region) the most appropriate site for placement of miniscrews [24-28](Figure 2).

Insertion technique

Temporary Anchorage Device (TAD) placement with a conventional straight driver or an engine mounted driver is problematic sometimes; for the reasons of directional control and lack of torque to drive the implant in hard palatal bone.

A dedicated palatal driver (L'il One, FavAnchorTMSAS, India) can be used to maintain adequate insertion angulation and torque while placing the mini screws (Figure 3). This unique design of the driver makes it very convenient to place the palatal implants with great ease and precision.

Screw design

Headless screws (Medusa, FavAnchorTMSAS, India) are recommended for palatal insertions as they're less bulky and in turn comfortable for the patient (Figure 4). Medusa is a uniquely designed screw which is recommended for palatal and closed (sub-apical) insertions. They're available in two sizes namely; short (2 x 10 mm) and long (2 x 12 mm). The hex head of the screw is small enough to have a smooth feel for the tongue (in MARPE cases) and big enough to fit in the driver for a secured insertion.

Activation protocol/schedule

Activation initially is done for 2 turns/day till development of diastema, followed by 1 turn/day till sufficient expansion has been achieved [16]. Activation schedule was followed as Table 1 [17].

Post-expansion assessment

Post expansion transverse measurements of frontonasal area, zygomatic arch and nasal cavity should be recorded and compared to the pre-treatment values to evaluate and compare the skeletal changes (Figure 5). Maximum expansion is usually seen in the nasal cavity [29], followed by zygomatic arch and frontonasal area.

Discussion

Various types of RPE appliances; tooth & tooth-tissue borne are available [3,4,30]. Due to maturation and adjacent articulations

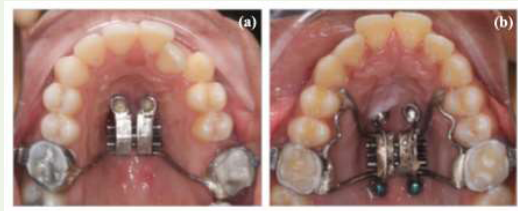


Figure 1: Types of MARPE appliances.

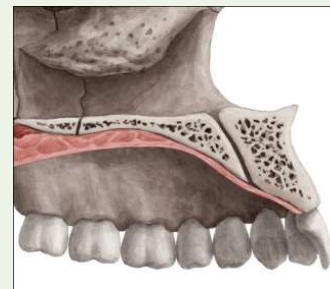


Figure 2: Palatal Anatomy.



Figure 3: L'il One Driver (FavAnchorTMSAS, India).



Figure 4: "Medusa" Screw (FavAnchorTMSAS, India).

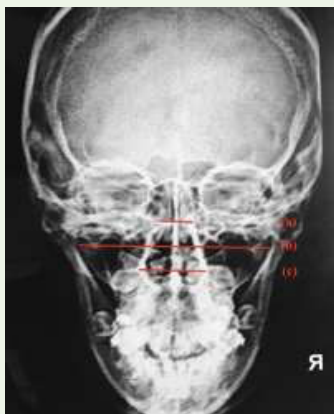

Figure 5: 'Comparison of skeletal parameters.

Table 1: Activation Schedule.

Age of the patient	Initial expansion rate	Expansion rate after opening of the diastema
13-16 years	3 turns/week	3 turns/week
16-19 years	1 turn/day	1 turn/day
19-30 years	2 turns/day	1 turn/day
Older patients (> 30 years)	> 2 turns/day	1 turn/day

in the midpalatal suture region [31,32]; palatal expansion in non-growing individuals has been shown to be less fruitful as compared to RPE in younger individuals [33-35]. This potential risk of tooth-borne appliances has been recognized in the literature and linked to resorption of buccal cortical bone, fenestrations, and gingival retraction [36].

Age is a vital factor in successful accomplishment of skeletal effects, as palatal expansion rapidly becomes inefficient after the early teens [1,37]. Thus, it was then believed that surgery is the only option for orthopaedic transverse correction [5]. Though, there are a few studies which show successful expansion in adults [4,38,39], there are still doubts whether they will represent general clinical situations.

Mouth breathing is a significant problem caused by nasomaxillary deficiency [40]; studies demonstrate that orthopaedic expansion can change the breathing pattern to nasal breathing [41,42]. RPE increases the nasal cavity volume [29,43], nasopharynx volume and cross-sectional areas of the upper airway [44-46].

More recent MARPE cases provide a clear picture using measurements from computed tomography [39,47]. Rigid interdigitation of palate in adults previously compelled clinician to perform limited lateral and midline osteotomies combined with fixed palatal expanders (SARPE) to effectively expand the maxillary skeletal base [48,49].

However, SARPE approach is a more invasive procedure; increases risk and the treatment costs for the patient [50,51]. The skeletal gain with MARPE appliances has been variable and was reported by Clement A as 61% of total expansion and was higher than that reported by Profitt (50%) [5,52], Kartalian, et al. (40%) [53], Lim, et al. (43.2%) and Garrett, et al. (55%) [54,55]. This can be attributed to

the better anchorage potential of miniscrews which Lee, et al. in 2017 in their FEM study claim can be enhanced by bicortical engagement of palatal miniscrews [56]. Tausche, et al. has documented that in their sample [57], 85% - 91% of expansion achieved was skeletal in nature which can be ascribed to surgical intervention done along with MARPE. Dental tipping in the buccal direction has been reported in previous studies of conventional RPE as well as MARPE [8,58]. Gurgel, et al. and Garib, et al. also reported some amount of buccal tipping with MARPE [48,59]. Thus, using a MARPE appliance, some amount of buccal tipping is inevitable though much less as compared to RPE, as teeth are still used as anchor units alongside miniscrews. Tendency of buccal tipping is directly proportional to resistance exerted by midpalatal suture. Moon, et al. in 2010 and later Kolge, et al. in 2018 reported greater changes in the degree of molar inclination than that of premolar inclination [20,26]. The higher density of the buccal cortical bone in the maxillary canine and premolar regions might have resulted in the greater buccal inclination of the first molar in comparison with that of the first premolar [58,60,61].

A conventional RPE is advantageous compared to MARPE appliances as they can be placed or removed in the outpatient clinic, does not usually require administration of local anaesthesia and are economical [50]; while placement of a MARPE appliance can be time consuming. Hygiene can be better maintained with MARPE appliances as compared to the conventional RPE appliances; since they were smaller in size, have less food retentive areas and permit better brushing and flossing [62].

Though, some claim MARPE to be more efficacious than conventional RPE [8,15,63], Lagravere MO in 2010 evaluated and compared treatment efficiency between MARPE and conventional RPE devices and affirmed that both have a similar skeletal expansion potential [8]. Thus, he further said; the decision to use a MARPE device should be based on operator preference and specific patient variables like missing/compromised anchor units. MARPE independent of any anchor units also allows a full bonded orthodontic therapy to be done at the same time as expansion. MARPE has been proved to be a viable treatment modality to correct a transverse maxillary deficiency in adults; with a considerably good success rate and stability [8,9,16,50,52,58,59,63-65].

While zygomatic arch expanded to a lesser extent, expansion of nasal cavity was much more evident, and thus can result in improvement of nasal breathing owing to increased air flow. Thus, by effectively increasing the nasal cavity volume, treatment with a MARPE appliance can improve the constricted airway, thus aiding in long-term stability [66,67].

Conclusion

Expansions achieved in the cases treated by MARPE are majorly skeletal expansion, as the appliance is a tooth-and-tissue borne appliance. It can be used in young adults from late teens to mid-twenties and exhibits a high success in this particular age group. Clinical observations suggest that MARPE prevents many of the adverse effects of RPE and should be considered as a preferred and effective alternative for the same.

References

1. McNamara JA, Brudon WL (2001) *Orthodontics and Dentofacial Orthopedics*. Needham Press, pp: 555.
2. Graber L, Vanarsdall R, Vig K, Graber L, Vanarsdall R, et al. (2011) *Orthodontics: Current Principles and Techniques* (5th edn). Philadelphia: Elsevier, pp: 944.
3. Bench RW (1998) The quad helix appliance. *Semin Orthod* 4: 331-337.
4. Handelman CS, Wang L, BeGole EA, Haas AJ (2000) Nonsurgical rapid maxillary expansion in adults: report on 47 cases using the Haas expander. *Angle Orthod* 70: 129-144.
5. Proffit WR, Fields HW, Sarver DM (2006) *Contemporary orthodontics* (4th edn.). Philadelphia: Elsevier, pp: 768.
6. Garrett BJ, Caruso JM, Rungcharassaeng K, Farrage JR, Kim JS, et al. (2008) Skeletal effects to the maxilla after rapid maxillary expansion assessed with cone-beam computed tomography. *Am J Orthod Dentofacial Orthop* 134: 8-9.
7. Basiftci FA, Karaman AI (2002) Effects of a modified acrylic bonded rapid maxillary expansion appliance and vertical chin cap on dentofacial structures. *Angle Orthod* 72: 61-71.
8. Lagravere MO, Carey J, Heo G, Toogood RW, Major PW (2010) Transverse, vertical, and anteroposterior changes from bone-anchored maxillary expansion vs traditional rapid maxillary expansion: a randomized clinical trial. *Am J Orthod Dentofacial Orthop* 137: 304.e1-e12.
9. Lee KJ, Park YC, Park JY, Hwang WS (2010) Miniscrew-assisted nonsurgical palatal expansion before orthognathic surgery for a patient with severe mandibular prognathism. *Am J Orthod Dentofacial Orthop* 137: 830-839.
10. MacGinnis M, Chu H, Youssef G, Wu KW, Machado AW, et al. (2014) The effects of Micro-Implant Assisted Rapid Palatal Expansion (MARPE) on the nasomaxillary Complex--A Finite Element Method (FEM) analysis. *Prog Orthod* 15: 52. [19]
11. Shapiro PA, Kokich VG (1988) Uses of implants in orthodontics. *Dent Clin North Am* 32: 539-550.
12. Smalley WM, Shapiro PA, Hohl TH, Kokich VG, Branemark PI (1988) Osseointegrated titanium implants for maxillofacial protraction in monkeys. *Am J Orthod Dentofacial Orthop* 94: 285-295.
13. Erverdi N, Okar I, Kucukkeles N, Arbak S (1994) A comparison of two different rapid palatal expansion techniques from the point of root resorption. *Am J Orthod Dentofacial Orthop* 106: 47-51.
14. Parr JA, Garetto LP, Wohlford ME, Arbuckle GR, Roberts WE (1997) Sutural expansion using rigidly integrated endosseous implants: an experimental study in rabbits. *Angle Orthod* 67: 283-290.
15. Harzer W, Reusser L, Hansen L, Richter R, Nagel T, et al. (2010) Minimally invasive rapid palatal expansion with an implant- supported hyrax screw. *Biomed Tech (Berl)* 55: 39-45.
16. Kim KB, Helmkamp ME (2012) Miniscrew implant-supported rapid maxillary expansion. *J Clin Orthod* 46: 608-612.
17. Carlson C, Sung J, McComb RW, Machado AW, Moon W (2016) Microimplant-assisted rapid palatal expansion appliance to orthopedically correct transverse maxillary deficiency in an adult. *Am J Orthod Dentofacial Orthop* 149: 716-728.
18. Moon W, Machado A (2013) Interview with Won Moon. *Dental Press J Orthod* 18: 12-28.
19. Suzuki H, Moon W, Previdente LH, Suzuki SS, Garcez AS, et al. (2016) Miniscrew Assisted Rapid Palatal Expander (MARPE): the quest for pure orthopedic movement. *Dental Press J Orthod* 21: 17-23.
20. Kolge NE, Patni VJ, Potnis SS, Kate SR, Fernandes FS, et al. (2018) Pursuit for optimum skeletal expansion: Case reports on Miniscrew Assisted Rapid Palatal Expansion (MARPE). *J Orthod Endod* 4: 9.
21. Marquezan M, Nojima LI, Freitas AO, Baratieri C, Alves Júnior M, et al. (2012) Tomographic mapping of the hard palate and overlying mucosa. *Braz Oral Res* 26: 36-42.
22. Lombardo L, Gracco A, Zampini F, Stefanoni F, Mollica F (2010) Optimal palatal configuration for miniscrew applications. *Angle Orthod* 80: 145-152.
23. Kyung SH, Hong SG, Park YC (2013) Distalization of maxillary molars with a midpalatal miniscrew. *J Clin Orthod* 37: 22-26.
24. Kang S, Lee SJ, Ahn SJ, Heo MS, Kim TW (2007) Bone thickness of the palate for orthodontic mini-implant anchorage in adults. *Am J Orthod Dentofacial Orthop* 131: S74-S81.
25. King KS, Lam EW, Faulkner MG, Heo G, Major PW (2007) Vertical bone volume in the paramedian palate of adolescents: a computed tomography study. *Am J Orthod Dentofacial Orthop* 132: 783-788.
26. Moon SH, Park SH, Lim WH, Chun YS (2010) Palatal bone density in adult subjects: implications for mini-implant placement. *Angle Orthod* 80: 137-144.
27. Kim HJ, Yun HS, Park HD, Kim DH, Park YC (2006) Soft-tissue and cortical-bone thickness at orthodontic implant sites. *Am J Orthod Dentofacial Orthop* 130: 177-182.
28. Motoyoshi M, Yoshida T, Ono A, Shimizu N (2007) Effect of cortical bone thickness and implant placement torque on stability of orthodontic mini-implants. *Int J Oral Maxillofac Implants* 22: 779-784.
29. Yılmaz A, Arman-Özçirpici A, Erken S, Polat-Özsoy Ö (2015) Comparison of short-term effects of mini- implant-supported maxillary expansion appliance with two conventional expansion protocols. *Eur J Orthod* 37: 556-564.
30. Mundstock KS, Barreto G, Meloti AF, Araujo MA, Santos-Pinto A, et al. (2007) Rapid maxillary expansion with the hyrax appliance: an occlusal radiographic evaluation study. *World J Orthod* 8: 277-284.
31. Persson M, Thilander B (1977) Palatal suture closure in man from 15 to 35 years of age. *Am J Orthod* 72: 42-52.
32. Melsen B, Melsen F (1982) The postnatal development of the palatomaxillary region studied on human autopsy material. *Am J Orthod* 82: 329-342.
33. Melsen B (1975) Palatal growth studied on human autopsy material. A histological micro radiographic study. *Am J Orthod* 68: 42-54.
34. Melsen B (1972) A histological study of the influence of sutural morphology and skeletal maturation of rapid palatal expansion in children. *Trans Eur Orthod Soc* 499-507.
35. Bazargani F, Feldmann I, Bondemark L (2013) Three-dimensional analysis of effects of rapid maxillary expansion on facial sutures and bones. *Angle Orthod* 83: 1074-1082.
36. Silverstein K, Quinn PD (1997) Surgically-assisted rapid palatal expansion for management of transverse maxillary deficiency. *J Oral Maxillofac Surg* 55: 725-727.
37. Kerbs A (1964) Midpalatal suture expansion studies by the implant method over a seven-year period. *Rep Congr Eur Orthod Soc* 40: 131-142.
38. Mew J (1997) Rapid maxillary expansion. *Angle Orthod* 67: 404.
39. Ghoneima A, Abdel-Fattah E, Hartsfield J, El-Bedwehi A, Kamel A, et al. (2011) Effects of rapid maxillary expansion on the cranial and circummaxillary sutures. *Am J Orthod Dentofacial Orthop* 140: 510-519.
40. Kilic N, Oktay H (2008) Effects of rapid maxillary expansion on nasal breathing and some naso-respiratory and breathing problems in growing children: a literature review. *Int J Pediatr Otorhinolaryngol* 72: 1595-1601.
41. Giancotti A, Greco M (2008) The use of bonded acrylic expander in patient with open-bite and oral breathing. *Eur J Paediatr Dent* 9: 3-8.
42. Chung JC (2006) Redirecting the growth pattern with rapid maxillary expander and chin cup treatment: changing breathing pattern from oral to nasal. *World J Orthod* 7: 236-253.
43. Smith T, Ghoneima A, Stewart K, Liu S, Eckert G, et al. Three-dimensional

- computed tomography analysis of airway volume changes after rapid maxillary expansion. *Am J Orthod Dentofacial Orthop* 141: 618-626.
44. Chang Y, Koenig LJ, Pruszynski JE, Bradley TG, Bosio JA, et al. (2013) Dimensional changes of upper airway after rapid maxillary expansion: a prospective cone-beam computed tomography study. *Am J Orthod Dentofacial Orthop* 143: 462-470.
 45. Kabalan O, Gordon J, Heo G, Lagravere MO (2015) Nasal airway changes in bone-borne and tooth-borne rapid maxillary expansion treatments. *Int Orthod* 13: 1-15.
 46. Oliveira De Felipe NL, Da Silveira AC, Viana G, Kusnoto B, Smith B, et al. (2008) Relationship between rapid maxillary expansion and nasal cavity size and airway resistance: short- and long-term effects. *Am J Orthod Dentofacial Orthop* 134: 370-382.
 47. Giuca MR, Pasini M, Galli V, Casani AP, Marchetti E, et al. (2009) Correlations between transversal discrepancies of the upper maxilla and oral breathing. *Eur J Paediatr Dent* 10: 23-28.
 48. Gurgel JA, Tiago CM, Normando D (2014) Transverse changes after surgically assisted rapid palatal expansion. *Int J Oral Maxillofac Surg* 43: 316-322.
 49. Kretschmer WB, Baciut G, Maciut M, Zoder K, Wnagerin K (2010) Stability of Le Fort I osteotomy in bimaxillary osteotomies: single-piece versus 3-piece maxilla. *J Oral Maxillofac Surg* 68: 372-380.
 50. Koudstaal MJ, Wolvius EB, Schulten AJM, Hop WC, Van der Wal KG (2009) Stability, tipping and relapse of bone-borne versus tooth-borne surgically assisted rapid maxillary expansion; a prospective randomized patient trial. *Int J Oral Maxillofac Surg* 38: 308-315.
 51. Maltagliati LA, Myiahira YI, Fattori L, Filho LC, Cardoso M (2013) Transversal changes in dental arches from non-extraction treatment with self-ligating brackets. *Dental Press J Orthod* 18: 39-45.
 52. Clement EA, Krishnaswamy NR (2017) Skeletal and dentoalveolar changes after skeletal anchorage-assisted rapid palatal expansion in young adults: A cone beam computed tomography study. *APOS Trends Orthod* 7: 113-119.
 53. Kartalian A, Gohl E, Adamian M, Enciso R (2010) Cone-beam computerized tomography evaluation of the maxillary dentoskeletal complex after rapid palatal expansion. *Am J Orthod Dentofacial Orthop* 138: 486-492.
 54. Lim HM, Park YC, Lee KJ, Kim KH, Choi YJ (2017) Stability of dental, alveolar, and skeletal changes after miniscrew-assisted rapid palatal expansion. *Korean J Orthod* 47: 313-322.
 55. Garrett BJ, Caruso JM, Rungcharassaeng K, Farrage JR, Kim JS, et al. (2008) Skeletal effects to the maxilla after rapid maxillary expansion assessed with cone-beam computed tomography. *Am J Orthod Dentofacial Orthop* 134: 8-9.
 56. Lee RJ, Moon W, Hong C (2017) Effects of monocortical and bicortical mini-implant anchorage on bone-borne palatal expansion using finite element analysis. *Am J Orthod Dentofacial Orthop* 151: 887-897.
 57. Tausche E, Hansen L, Hietschold V, Lagravère MO, Harzer W (2007) Three-dimensional evaluation of surgically assisted implant bone-borne rapid maxillary expansion: a pilot study. *Am J Orthod Dentofacial Orthop* 131: 92-99.
 58. Christie KF, Boucher N, Chung CH (2010) Effects of bonded rapid palatal expansion on the transverse dimensions of the maxilla: a cone-beam computed tomography study. *Am J Orthod Dentofacial Orthop* 137: S79-S85.
 59. Garib DG, Henriques JF, Janson G, de Freitas MR, Fernandes AY (2006) Periodontal effects of rapid maxillary expansion with tooth-tissue-borne and tooth-borne expanders: a computed tomography evaluation. *Am J Orthod Dentofacial Orthop* 129: 749-758.
 60. Rungcharassaeng K, Caruso JM, Kan JY, Kim J, Taylor G (2007) Factors affecting buccal bone changes of maxillary posterior teeth after rapid maxillary expansion. *Am J Orthod Dentofacial Orthop* 132: 428.e1-8.
 61. Corbridge JK, Campbell PM, Taylor R, Ceen RF, Buschang PH (2011) Transverse dentoalveolar changes after slow maxillary expansion. *Am J Orthod Dentofacial Orthop* 140: 317-325.
 62. Lee TC, McGrath CP, Wong RW, Rabie AB (2008) Patients' perceptions regarding microimplant as anchorage in orthodontics. *Angle Orthod* 78: 228-233.
 63. Garib DG, Navarro R, Francischone CE, Oltramari PV (2008) Rapid maxillary expansion using palatal implants. *J Clin Orthod* 42: 665-671.
 64. Park JJ, Park YC, Lee KJ, Cha JY, Tahk JH, et al. (2017) Skeletal and dentoalveolar changes after mini screw-assisted rapid palatal expansion in young adults: A cone-beam computed tomography study. *Korean J Orthod* 47: 77-86.
 65. Choi SH, Shi KK, Cha JY, Park YC, Lee KJ (2016) Nonsurgical miniscrew-assisted rapid maxillary expansion results in acceptable stability in young adults. *Angle Orthod* 86: 713-720.
 66. Ngan P, Moon W (2015) Evolution of Class III treatment in orthodontics. *Am J Orthod Dentofacial Orthop* 148: 22-36.
 67. Moon W, Khulla R (2014) Class III orthopedic treatment with skeletal anchorage. Potomac, Md: Bentham, pp: 116-150.